

Managing Incidental Thyroid Nodules Detected on Imaging: White Paper of the ACR Incidental Thyroid Findings Committee

Jenny K. Hoang, MBBS^a, Jill E. Langer, MD^b, William D. Middleton, MD^c,
Carol C. Wu, MD^d, Lynwood W. Hammers, DO^e, John J. Cronan, MD^f,
Franklin N. Tessler, MD, CM^g, Edward G. Grant, MD^h, Lincoln L. Berland, MD^g

The incidental thyroid nodule (ITN) is one of the most common incidental findings on imaging studies that include the neck. An ITN is defined as a nodule not previously detected or suspected clinically, but identified by an imaging study. The workup of ITNs has led to increased costs from additional procedures, and in some cases, to increased risk to the patient because physicians are naturally concerned about the risk of malignancy and a delayed cancer diagnosis. However, the majority of ITNs are benign, and small, incidental thyroid malignancies typically have indolent behavior. The ACR formed the Incidental Thyroid Findings Committee to derive a practical approach to managing ITNs on CT, MRI, nuclear medicine, and ultrasound studies. This white paper describes consensus recommendations representing this committee's review of the literature and their practice experience.

Key Words: Incidental findings, thyroid nodule, thyroid cancer, imaging, incidentaloma

J Am Coll Radiol 2014;■:■-■. Copyright © 2014 American College of Radiology

FOREWORD

This white paper is not meant to comprehensively review the interpretation and management of thyroid nodules, but to provide general guidance for managing incidentally discovered thyroid nodules (ITNs). Individual care will, of course, vary depending on each patient's specific circumstances, the clinical environment and available resources, and the judgment of the practitioner. In addition, the term "guidelines" has intentionally not been used in this white paper, to avoid the implication that the contents represent a component of the ACR Practice Parameters and Technical Standards, or of the ACR Appropriateness Criteria; they do not. This white paper represents the collective experience of

the Incidental Thyroid Findings Committee and does not represent official ACR policy. For these reasons, this white paper should not be used to establish the legal standard of care in any particular situation.

INTRODUCTION

Although the rapid increase in use of imaging examinations in the past 30 years has abated, continued improvements in the quality of images, along with concerns about litigation and other factors, have led to a high number of incidental findings reported by radiologists [1,2]. The ITN is one of the most common incidental findings on imaging studies that include the neck. It is defined as a nodule identified by an imaging study that was not previously detected or suspected clinically. There is currently a paucity of guidance from professional organizations on management of ITNs, and high variability in reporting of ITNs by radiologists [3-5].

Added to the problem of an increased rate of reporting of ITNs, and variability in reporting, is the accessibility of thyroid nodules to biopsy and the low threshold for biopsy. Fine-needle aspiration (FNA) is a very effective and safe test for determining the histology of the ITN. However, unless the cytology result is definitively benign or malignant, patients may embark on a process of further investigations and procedures that may include surveillance, repeat biopsy, and diagnostic surgery. This process results in anxiety and

^aDuke University Medical Center, Durham, North Carolina.

^bThe Perelman School of Medicine at the University of Pennsylvania, Philadelphia, Pennsylvania.

^cWashington University School of Medicine, St. Louis, Missouri.

^dMassachusetts General Hospital, Boston, Massachusetts.

^eHammers Healthcare Imaging, LLC, and Yale School of Medicine, New Haven, Connecticut.

^fBrown University, Providence, Rhode Island.

^gUniversity of Alabama at Birmingham, Birmingham, Alabama.

^hKeck School of Medicine, University of Southern California, Los Angeles, California.

Corresponding author and reprints: Jenny K. Hoang, MBBS, Duke University Medical Center, Department of Radiology, Box 3808, Erwin Road, Durham, NC 27710; e-mail: jennykh@gmail.com. Twitter handle: @JennyKHoang.

potential morbidity for the patient, and is a cumulatively costly problem for the health care system.

PROJECT OBJECTIVES

The objective of this project was to develop medically appropriate approaches to managing ITNs detected on a variety of imaging modalities. Benefits anticipated from this effort include the following:

- Distinguishing between ITNs that do versus do not require dedicated thyroid ultrasound;
- Reducing the downstream risks and costs by reducing the likelihood that an ITN will lead to a dedicated thyroid ultrasound and potential consequences following FNA;
- Achieving greater consistency in recognizing, reporting, and managing ITNs;
- Providing guidance to radiologists who are concerned about not reporting or recommending further workup of ITNs that later prove to be clinically important; and
- Helping focus research efforts to lead to an evidence-based approach to ITNs.

PROJECT HISTORY AND CONSENSUS PROCESS

The Incidental Thyroid Findings Committee (hereafter the Committee) was formed under the auspices of the ACR in 2013. The intent was to develop guidance analogous to the white papers produced by the ACR Incidental Finding Committee on abdominal and pelvic incidental findings on CT and MRI [6,7].

The Committee participants were recruited from members of the ACR and included academic and private practice radiologists with subspecialties in sonography, abdominal imaging, neuroradiology, and chest imaging. Three subcommittees were established to address management of ITNs detected on CT and MRI, nuclear medicine, and ultrasound. Each subcommittee was tasked with developing modality-specific guidance based on review of the literature and practice experience. The recommendations were submitted to other subcommittee members for further comments and discussion. After multiple revisions, the draft was distributed to the entire Committee for additional review to achieve consensus and arrive at a final manuscript.

ELEMENTS, RECOMMENDATIONS, AND FLOWCHARTS

In the flowcharts within this white paper, the algorithms use yellow boxes for steps that involve data that affect management; green boxes to represent action steps; and red boxes to indicate that no further action is required. Radiologists are unlikely to be aware of all relevant clinical factors at the time an ITN is discovered. However, these recommendations do not apply to patients with increased risk for thyroid carcinoma, those who

may be symptomatic from thyroid disease, or pediatric patients.

The Committee recognizes that radiologists will have different preferences regarding whether and how to report ITNs. If the ITN does not meet criteria for further evaluation according to the flowcharts, the Committee believes that determination of whether the ITN is mentioned in the body of the radiology report should be left to the discretion of the radiologist. However, the Committee recommends against both mentioning an ITN in the Impression/Conclusion section of the report, and recommending further evaluation or follow-up imaging, if the ITN does not meet criteria for further evaluation.

NATURE AND SCOPE OF THE PROBLEM

Prevalence of ITNs and Risk of Malignancy

Thyroid nodules are very common in the adult population. A large autopsy study published in 1955 found that 50% of patients with no clinical history of thyroid disease had thyroid nodules, and the majority were multiple [8]. Like autopsy, imaging can reveal subclinical thyroid nodules. With increased use of imaging for screening, diagnosis, and treatment response evaluation over the past three decades, ITNs have become a common finding that may be recommended for workup. ITNs are seen in 20%-67% of ultrasound studies [9,10], up to 25% of contrast-enhanced chest CT scans [11], and 16%-18% of CT and MR scans of the neck [12,13]. Two large systematic reviews found that prevalence of ITNs on Fluorodeoxyglucose (¹⁸FDG)-PET scans is lower, at 1%-2% [14,15].

The malignancy rate in ITNs depends on the techniques used to diagnose malignancy and the nodule workup rate. Harach et al [16] searched for thyroid cancer at autopsy and found occult papillary cancers in 36% of 101 thyroid glands. Therefore, the fact that a significant portion of patients with ITNs who receive workup will be diagnosed with malignancy is not surprising. Malignancy rates of ITNs detected by imaging vary widely depending on selection biases in the studies. In one ultrasound report, the malignancy rate was 12% in a cohort that included only ITNs that underwent biopsies [17], but in a population-based study that linked patients who had thyroid ultrasound to a cancer registry, the malignancy rate was 1.6% in patients with ≥ 1 thyroid nodules [18]. The malignancy rate of ITNs detected on CT and MRI ranges from 0% to 11% [12,13,19,20], whereas the malignancy rate of ITNs with focal uptake on FDG-PET scans is much higher, at 33%-35% [14,15].

Problems with Initiating Workup

Although FNA of ITNs carries minimal risk to the patient, the inability of cytology to definitively establish a benign diagnosis in a subset of nonmalignant nodules may expose a substantial number of patients to repeat biopsy or lead to diagnostic surgical removal of benign

nodules. Retrospective studies show that 25%-41% of patients who undergo FNA for ITNs proceed to surgery, and 36%-75% of these patients will have benign nodules [21-23]. The rate of benign results is this high because cytology is inherently limited for the diagnoses of “follicular neoplasm” and “suspicion for follicular neoplasm.” Differentiation between follicular carcinoma and adenoma can only be made on diagnostic lobectomy, and only 26% of these patients ultimately have malignancy [24]. Patients with nodules reported as “malignant” or “suspicious for malignancy” on cytology are advised to undergo surgical resection, but even 25% of patients in the “suspicious for malignancy” category have benign results [24]. Of those who do not undergo surgery, many are referred for follow-up ultrasound.

Small Thyroid Cancers Are Indolent

Although early cancer diagnosis and treatment may lead to more-favorable outcomes in some types of malignancies, this effect is not proven for small incidental thyroid cancers. Compared with malignancies discovered clinically, incidentally discovered thyroid cancers are more likely to be papillary carcinomas, more likely to be smaller in size, and less likely to develop metastases [25,26]. Although radiologists fear failure in detecting malignancies, the prognosis for most small, localized papillary cancers is excellent, even without treatment. As previously discussed, Harach et al [16] found that the background rate of subclinical thyroid cancers at autopsy is at least 36%. In clinical studies, an observational trial of 340 patients with untreated papillary microcarcinomas found no cancer deaths over a 10-year period, and new nodal metastases in only 3% of patients [27].

Additional evidence supporting the indolent behavior of thyroid cancer comes from national cancer registries. Davies et al [28] reported that the incidence of thyroid cancer nearly tripled from 1975 to 2009, with a disproportionate increase in small papillary cancers. Despite dramatic changes in incidence, the mortality rate from thyroid cancer was stable. The authors concluded that the increase in incidence of thyroid cancer was a result of overdiagnosis, and that diagnosing and treating these cancers produced no survival benefit.

ITNs DETECTED ON CT AND MRI

Implications of Imaging and Clinical Features

An ITN can be detected on CT or MRI scans that cover the lower neck or upper mediastinum. CT of the chest is responsible for the majority of ITNs [5]. These scans can be performed with or without intravenous contrast, but thyroid nodules can readily be seen even without contrast, because normal thyroid tissue has intrinsic high attenuation on CT, and a lower T2 signal on MRI.

CT and MRI examinations have no reliable signs to indicate that a thyroid nodule is benign or malignant. The reason is at least partially that CT and MRI do not

have adequate spatial resolution to display some findings commonly used in sonography that are known to be helpful (such as cystic changes, microcalcifications, and lobulated or irregular margins). CT findings in ITNs match the sonographic findings in only 53% of patients, and CT misses other thyroid nodules or multinodularity in 40% of patients [20]. On MRI, both malignant and benign thyroid nodules can have isointense T1 and hyperintense T2 signals [29]. Because of this absence of reliable imaging features of benignity or malignancy on CT and MRI, the imaging feature that primarily directs further evaluation is nodule size.

Although nodule size has a limited correlation with the risk of malignancy, size thresholds are used in previous guidelines from other professional organizations because size affects prognosis in malignant nodules [30-32]. Thyroid cancers <2 cm generally have an indolent course, with a 99.9% 10-year survival rate, and failure to diagnose these cancers is unlikely to affect morbidity and mortality [13,33]. Although CT and MRI may underestimate the size of the nodule compared to ultrasound and pathology [20], it is reasonable to use measurements on CT and MRI examinations, especially if the size thresholds for workup are <2 cm.

Patient age is a clinical factor to consider when managing ITNs. Young patients undergo CT and MRI imaging less frequently, so they comprise only a small proportion of patients (<7%) with imaging-detected ITNs [13,20,21]. However, the prevalence of benign thyroid nodules increases with increasing patient age, so the ratio of malignant to benign thyroid nodules may be higher in young patients. This possibility is supported in a study by Shetty et al [20], who found a higher rate of malignancy in patients age ≤ 35 years who had an ITN detected on CT. In addition, diagnosis of an asymptomatic cancer may be more important in a younger patient. Ito et al [34] found a slightly higher risk of tumor progression in young patients (age <40 years) with subclinical, low-risk, papillary thyroid cancers who undergo observation rather than surgery.

The decision to evaluate further should also take into account the patient's life expectancy, based primarily on age and comorbidities. As many CT and MRI scans are performed for surveillance and diagnosis of malignancies or vascular diseases, a high proportion of these patients have serious comorbidities and are older [5]. In such patients, the diagnosis and treatment of thyroid cancer is unlikely to alter their quality of life or life expectancy.

Existing Recommendations for ITNs Detected on CT and MRI

The American Thyroid Association [32] recommends that ultrasound be used to evaluate all thyroid nodules seen on CT, MRI, and ^{18}F FDG-PET scans, but they do not specify the characteristics of thyroid nodules that should be considered potentially more suspicious. Recently, a categorization method known as the 3-tiered

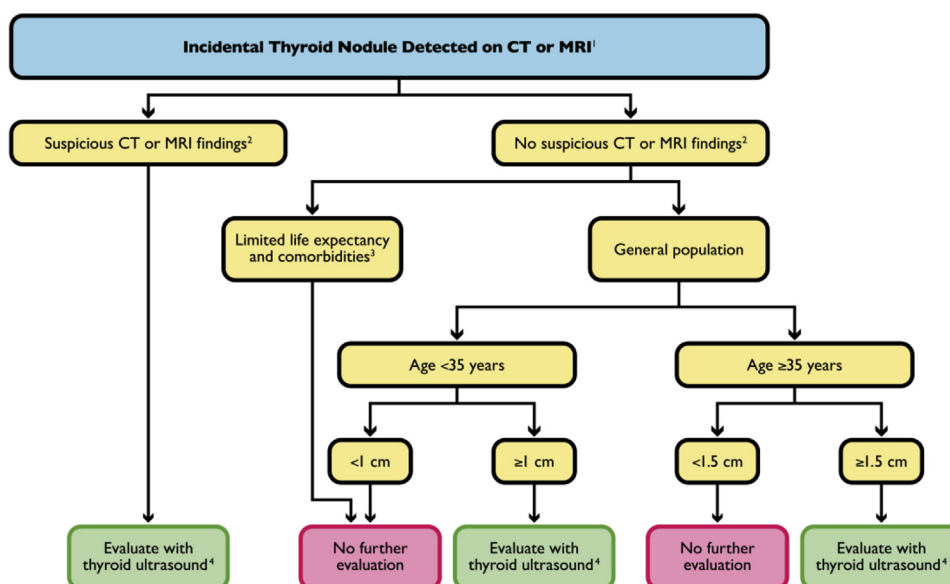


Fig 1. Flowchart for incidental thyroid nodules (ITNs) detected on CT or MRI. ¹The recommendations are offered as general guidance and do not apply to all patients, such as those with clinical risk factors for thyroid cancer. ²Suspicious CT/MRI features include: abnormal lymph nodes and/or invasion of local tissues by the thyroid nodule. Abnormal lymph node features include: calcifications, cystic components, and/or increased enhancement. Nodal enlargement is less specific for thyroid cancer metastases, but further evaluation could be considered if an ITN has ipsilateral nodes >1.5 cm in short axis for jugulodigastric lymph nodes, and >1 cm for other lymph nodes. ³Limited life expectancy and comorbidities that increase the risk of treatment or are more likely to cause morbidity and mortality than the thyroid cancer itself, given the nodule size; see text for details. Patients with comorbidities or limited life expectancy should not have further evaluation of the ITN, unless it is warranted clinically, or specifically requested by the patient or referring physician. ⁴Further management of the ITN after thyroid ultrasound, including fine-needle aspiration, should be based on ultrasound findings.

system has been proposed for specifically guiding the evaluation of ITNs detected with CT, MRI, and PET [13,21,35,36]. The method is based on the patient's age and imaging findings. According to this system, further evaluation with thyroid ultrasound should be considered for 3 groups (tiers): (1) nodules with certain imaging features deemed to be high risk (suspicious lymph nodes, local invasion, PET avid nodule); (2) nodules ≥ 1 cm in patients age <35 years; and (3) nodules ≥ 1.5 cm in patients age ≥ 35 years.

In 2 retrospective studies, the 3-tiered system was found to reduce the number of ITNs undergoing further evaluation [13,21]. Compared with an academic institution's clinical practice without specific guidelines, the 3-tiered system for ITNs detected with CT, MRI, or PET/CT would lead to a 35% reduction in ultrasound-guided biopsy [21]. In a different study of patients with ITNs on neck CT, the 3-tiered system would result in a 46% reduction in recommendations for ultrasound compared to a 1-cm size cutoff [13]. A third study estimated the risk of missing an incidental malignancy with the 3-tiered system and found that the false-negative rate of the 3-tiered system was 13% [37]. However, incidental malignancies detected with CT, MRI, or PET/CT comprised only 11% of thyroid malignancies, so the 3-tiered system would miss only 1.2% of all thyroid

malignancies. Furthermore, those that would not be worked up by the 3-tiered system were all small papillary cancers.

Management Recommendations for ITNs Detected on CT and MRI

The Committee's guidance for managing ITNs detected on CT or MRI is illustrated in the flowchart in Figure 1. The CT or MRI study should first be evaluated for suspicious features associated with the ITN, including abnormal lymph nodes or signs of local invasion, neither of which is likely in a patient without thyroid-related symptoms. Abnormal lymph nodes are defined as enlarged nodes or those with cystic change, calcification, or increased enhancement. Lymph nodes in levels IV and VI are especially suspicious for thyroid cancer metastases. Enlarged lymph nodes have size >1.5 cm in short axis for jugulodigastric nodes, and >1 cm for other nodes, but size alone has low specificity, regardless of imaging modality. The Committee recommends that all patients with ITNs with suspicious features have ultrasound to confirm the findings, with consideration for FNA.

For patients with no suspicious imaging features of an ITN, comorbidities or limited life expectancy may increase the risk of morbidity and mortality more than the

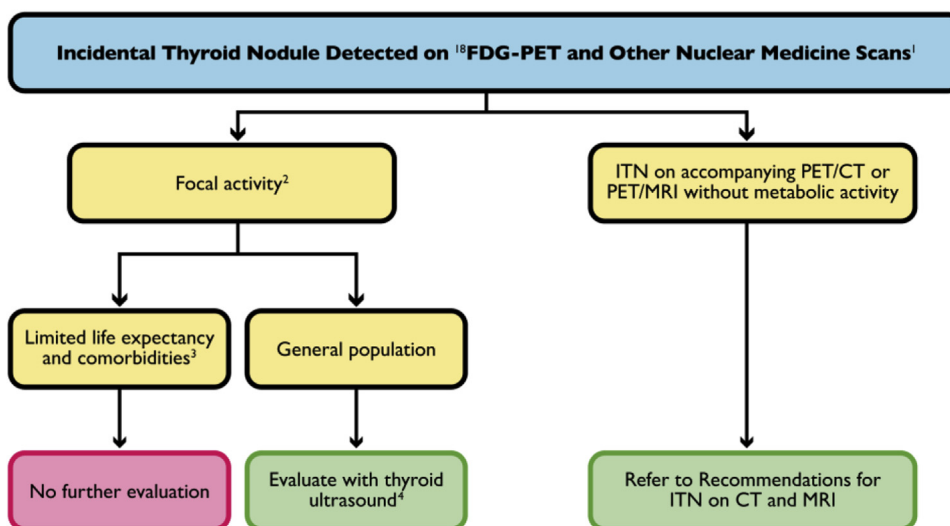


Fig 2. Flowchart for incidental thyroid nodules (ITNs) detected on ^{18}F -FDG-PET and other nuclear medicine studies. ¹The recommendations are offered as general guidance and do not apply to all patients, such as those with clinical risk factors for thyroid cancer. ²Focal uptake may include one or more sites. Diffuse uptake in the thyroid without a corresponding mass is not considered to be focal. ³Limited life expectancy and comorbidities that increase the risk of treatment or are more likely to cause morbidity and mortality than the thyroid cancer itself, given the nodule size; see text for details. Patients with comorbidities or limited life expectancy should not have further evaluation of the ITN, unless it is warranted clinically, or specifically requested by the patient or referring physician. ⁴Further management of the ITN after thyroid ultrasound should include fine-needle aspiration for PET-avid ITN regardless of the ultrasound findings; see text for details. Avid nodules on other nuclear medicine scans can have ultrasound with the decision to perform FNA based on findings seen on the dedicated thyroid ultrasound.

thyroid cancer itself, so the Committee recommends that they not undergo further evaluation. Exceptions include cases in which the referring clinician believes further evaluation is warranted, and in which the patient or referring physician specifically requests it.

In the general population with normal life expectancy and without suspicious imaging features, patient age and nodule size should determine the need for workup. The Committee recommends further evaluation with ultrasound for patients age <35 years with nodules measuring ≥ 1 cm in the axial plane. If the patient is age ≥ 35 years, the size cutoff in the axial plane for further evaluation is raised to 1.5 cm. For patients with multiple thyroid nodules, the flowchart in Figure 1 should be applied to the largest thyroid nodule. Patients with incidental, heterogeneous, enlarged thyroid glands should have further workup with dedicated ultrasound if they do not have serious comorbidities or limited life expectancy.

ITNs DETECTED ON ^{18}F -FDG-PET STUDIES

Implications of Imaging and Clinical Features

The main source of ITNs on nuclear medicine imaging is ^{18}F -FDG-PET scans. Focal increased metabolic activity on ^{18}F -FDG-PET studies is very indicative of malignancy regardless of the sonographic findings on subsequent workup. Two studies found that metabolically active nodules without any suspicious sonographic findings still

had a relatively high malignancy rate of 11%-13% [38,39]. Other important factors to consider in workup of patients with a metabolically active ITN are comorbidities and life expectancy as previously described for CT and MR.

Management Recommendations for ITNs Detected on ^{18}F -FDG-PET Scans

The Committee's guidance for managing ITNs detected on ^{18}F -FDG-PET scans is illustrated by the flowchart in Figure 2. In the general population, for focal metabolic activity in the thyroid detected on ^{18}F -FDG-PET scans with or without a corresponding thyroid nodule detected on CT, both dedicated thyroid ultrasound and FNA of the PET-avid lesion should be performed. In patients with serious comorbidities or limited life expectancy, no further evaluation of the ITN is recommended unless the referring clinician believes it is warranted, or it is specifically requested by the patient or referring physician.

ITNs Detected on Other Nuclear Imaging Studies

ITNs can be detected on nuclear medicine studies such as $^{99\text{m}}\text{Tc}$ -methoxyisobutylisonitrile (MIBI) and ^{111}In -octreotide scans, but these are uncommon sources for revealing ITNs [21,23]. A review of 101 incidental thyroid malignancies over a decade at an academic center found only one patient with an incidental cancer that was detected on a nuclear medicine study other than a PET scan (octreotide scan) [25].

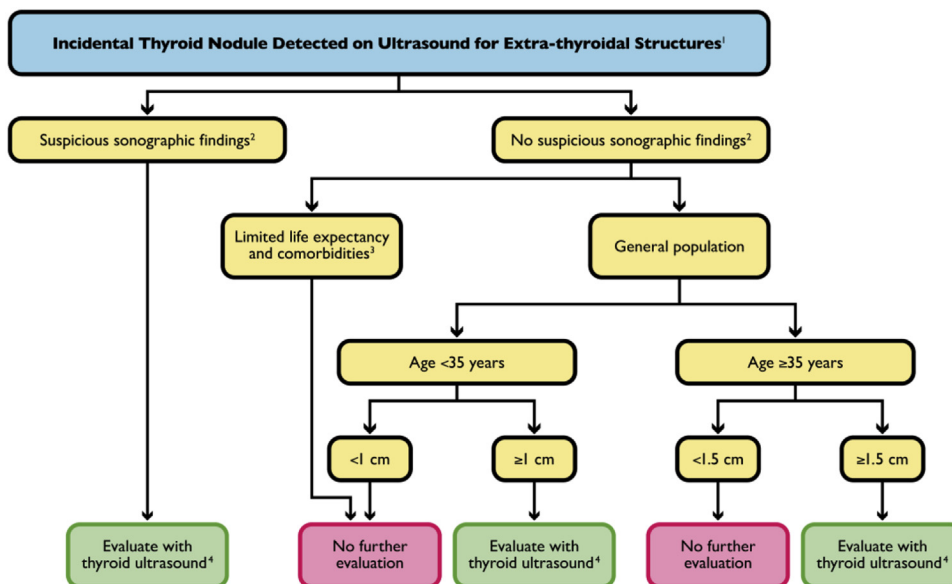


Fig 3. Flowchart for incidental thyroid nodules (ITNs) detected on ultrasound for extrathyroidal structures. ¹The recommendations are offered as general guidance and do not apply to all patients, such as those with clinical risk factors for thyroid cancer. ²Suspicious ultrasound features include microcalcifications, marked hypoechogenicity, lobulated or irregular margins, and taller-than-wide shape on transverse view. In most cases, suspicious features may not be completely evaluated. ³Limited life expectancy and comorbidities that increase the risk of treatment or are more likely to cause morbidity and mortality than the thyroid cancer itself, given the nodule size; see text for details. Patients with comorbidities or limited life expectancy should not have further evaluation of the ITN, unless it is warranted clinically, or specifically requested by the patient or referring physician. ⁴Further management of the ITN, including fine-needle aspiration, should be based on the findings seen on the dedicated thyroid ultrasound.

Both thyroid malignancies and adenomas can have uptake on MIBI and octreotide scans [40,41]. Two small series of selected patients with incidental MIBI-avid thyroid nodules show that the rate of malignancy varies from 22%–66% [40,42]. No studies report the malignancy rate in thyroid nodules detected on octreotide scans.

The Committee recommends that the general population have dedicated thyroid ultrasound for avid nodules on MIBI and octreotide scans, with the need for FNA determined by sonographic criteria (Fig. 2). In patients with serious comorbidities or limited life expectancy, the Committee recommends no further evaluation of the ITN unless clinically warranted, in the judgment of the referring clinician, or unless specifically requested by the patient or referring physician.

ITNs DETECTED ON ULTRASOUND

Implications of Imaging and Clinical Features

ITNs are commonly detected during the course of thyroid ultrasound examinations performed for symptoms or a palpable nodule. Therefore, such nodules do not constitute incidental findings, and these recommendations do not apply [31,32,43]. However, the situation differs when an ITN is detected during sonography of extra-thyroidal structures, such as the carotid arteries, salivary glands, cervical lymph nodes,

parathyroid glands, and miscellaneous neck masses. Documentation of findings for the entire thyroid may be limited in these situations, and a decision about whether to perform a dedicated thyroid ultrasound should be influenced by life expectancy, patient age, and nodule size, as previously described for CT and MRI (Fig. 1). Such examinations should be conducted by personnel with expertise in performing dedicated thyroid ultrasound examinations.

Management Recommendations for ITNs Detected on Ultrasound

The Committee's guidance for managing ITNs detected on ultrasound of extrathyroidal structures is illustrated by the flowchart in Figure 3. First, the ultrasound should be evaluated for suspicious features associated with the ITN. Suspicious features that have been described in the literature include microcalcifications, marked hypoechogenicity, lobulated or irregular margins, and taller-than-wide shape on transverse view [30,44,45]. In some cases, suspicious features may not be completely evaluated or recorded on the images, but if any suspicious features are present, patients should have a dedicated thyroid ultrasound.

If no suspicious imaging features are present, and the patient has serious comorbidities or limited life expectancy, further evaluation is not recommended unless the referring clinician believes it is warranted or it is

specifically requested by the patient or referring physician. In the general population without suspicious imaging features, patients age <35 years with nodules measuring ≥ 1 cm should have further evaluation with ultrasound. If the patient is age ≥ 35 years, the size cutoff for further evaluation is raised to 1.5 cm.

FUTURE COMMITTEE OBJECTIVES

The Committee hopes that these recommendations will become widely applied. The ACR is developing methods to make these recommendations accessible electronically. The Committee recommends that the concepts, terminology, and parameters discussed in this article become the basis for future research to advance scientific evidence regarding incidental findings.

TAKE-HOME POINTS

- In patients age <35 years with an ITN detected on CT, MRI, or extrathyroidal ultrasound, the Committee recommends further evaluation with dedicated thyroid ultrasound if the nodule is ≥ 1 cm and has no suspicious imaging features, and if the patient has normal life expectancy.
- In patients age ≥ 35 years with an ITN detected on CT, MRI, or extrathyroidal ultrasound, the Committee recommends further evaluation with dedicated thyroid ultrasound if the nodule is ≥ 1.5 cm and has no suspicious imaging features, and if the patient has normal life expectancy.
- In patients with focal metabolic activity in the thyroid on ^{18}F FDG-PET, the Committee recommends both dedicated thyroid ultrasound and FNA of the PET-avid lesion if the patient has normal life expectancy.
- In patients with focal metabolic activity in the thyroid on other nuclear medicine studies, the Committee recommends dedicated thyroid ultrasound if the patient has normal life expectancy.

REFERENCES

1. Smith-Bindman R, Miglioretti DL, Johnson E, et al. Use of diagnostic imaging studies and associated radiation exposure for patients enrolled in large integrated health care systems, 1996-2010. *JAMA* 2012;307:2400-9.
2. Lang K, Huang H, Lee DW, Federico V, Menzin J. National trends in advanced outpatient diagnostic imaging utilization: an analysis of the medical expenditure panel survey, 2000-2009. *BMC Med Imaging* 2013;13:40.
3. Hoang JK, Riofrio A, Bashir MR, Kranz PG, Eastwood JD. High variability in radiologists' reporting practices for incidental thyroid nodules detected on CT and MRI. *AJNR Am J Neuroradiol* 2014;35:1190-4.
4. Lehnert BE, Sandstrom CK, Gross JA, Dighe M, Linnau KF. Variability in management recommendations for incidental thyroid nodules detected on CT of the cervical spine in the emergency department. *J Am Coll Radiol* 2014;11:681-5.
5. Grady AT, Sosa JA, Tanpitukpongse TP, Choudhury KR, Gupta RT, Hoang JK. Radiology reports for incidental thyroid nodules on CT and MRI: high variability across subspecialties. *AJNR Am J Neuroradiol* 2014. Published ahead of print on August 21, 2014.
6. Berland LL, Silverman SG, Gore RM, et al. Managing incidental findings on abdominal CT: white paper of the ACR Incidental Findings Committee. *J Am Coll Radiol* 2010;7:754-73.
7. Berland LL. Overview of white papers of the ACR Incidental Findings Committee II on adnexal, vascular, splenic, nodal, gallbladder, and biliary findings. *J Am Coll Radiol* 2013;10:672-4.
8. Mortensen JD, Woolner LB, Bennett WA. Gross and microscopic findings in clinically normal thyroid glands. *J Clin Endocrinol Metab* 1955;15:1270-80.
9. Ezzat S, Sarti DA, Cain DR, Braunstein GD. Thyroid incidentalomas. Prevalence by palpation and ultrasonography. *Arch Intern Med* 1994;154:1838-40.
10. Rad M, Zakavi S, Layegh P, Khooei A, Bahadori A. Incidental thyroid abnormalities on carotid color doppler ultrasound: frequency and clinical significance. *J Med Ultrasound* 2014. Published ahead of print on June 3, 2014.
11. Ahmed S, Horton KM, Jeffrey RB Jr, Sheth S, Fishman EK. Incidental thyroid nodules on chest CT: review of the literature and management suggestions. *AJR Am J Roentgenol* 2010;195:1066-71.
12. Yousem DM, Huang T, Loevner LA, Langlotz CP. Clinical and economic impact of incidental thyroid lesions found with CT and MR. *AJNR Am J Neuroradiol* 1997;18:1423-8.
13. Nguyen XV, Choudhury KR, Eastwood JD, et al. Incidental thyroid nodules on CT: evaluation of 2 risk-categorization methods for work-up of nodules. *AJNR Am J Neuroradiol* 2013;34:1812-7.
14. Soelberg KK, Bonnema SJ, Brix TH, Hegedus L. Risk of malignancy in thyroid incidentalomas detected by ^{18}F -fluorodeoxyglucose PET: a systematic review. *Thyroid* 2012;22:918-25.
15. Shie P, Cardarelli R, Sprawls K, Fulda KG, Taur A. Systematic review: prevalence of malignant incidental thyroid nodules identified on fluorine-18 fluorodeoxyglucose PET. *Nucl Med Commun* 2009;30:742-8.
16. Harach HR, Franssila KO, Wasenius VM. Occult papillary carcinoma of the thyroid. A "normal" finding in Finland. A systematic autopsy study. *Cancer* 1985;56:531-8.
17. Nam-Goong IS, Kim HY, Gong G, et al. Ultrasonography-guided fine-needle aspiration of thyroid incidentaloma: correlation with pathological findings. *Clin Endocrinol (Oxf)* 2004;60:21-8.
18. Smith-Bindman R, Lebda P, Feldstein VA, et al. Risk of thyroid cancer based on thyroid ultrasound imaging characteristics: results of a population-based study. *JAMA Intern Med* 2013;173:1788-96.
19. Yoon DY, Chang SK, Choi CS, et al. The prevalence and significance of incidental thyroid nodules identified on CT. *J Comput Assist Tomogr* 2008;32:810-5.
20. Shetty SK, Maher MM, Hahn PF, Halpern EF, Aquino SL. Significance of incidental thyroid lesions detected on CT: correlation among CT, sonography, and pathology. *AJR Am J Roentgenol* 2006;187:1349-56.
21. Hobbs HA, Bahl M, Nelson RC, et al. Journal Club: incidental thyroid nodules detected at imaging: can diagnostic workup be reduced by use of the Society of Radiologists in Ultrasound recommendations and the three-tiered system? *AJR Am J Roentgenol* 2014;202:18-24.
22. Kroeker TR, le Nobel G, Merdad M, Freeman JL. Outcomes of incidentally discovered thyroid nodules referred to a high-volume head and neck surgeon. *Head Neck* 2014;36:126-9.
23. Bahl M, Sosa JA, Nelson RC, Hoang JK. Imaging-detected incidental thyroid nodules that undergo surgery: a single-center experience over 1 year. *AJNR Am J Neuroradiol* 2014. Published ahead of print on June 26, 2014.
24. Bongiovanni M, Spitale A, Faquin WC, Mazzucchelli L, Baloch ZW. The Bethesda System for Reporting Thyroid Cytopathology: a meta-analysis. *Acta Cytol* 2012;56:333-9.
25. Bahl M, Sosa JA, Nelson RC, Esclamado RM, Choudhury KR, Hoang JK. Trends in incidentally identified thyroid cancers over a decade: a retrospective analysis of 2,090 surgical patients. *World J Surg* 2014;38:1312-7.

26. Bahl M, Sosa JA, Nelson RC, Hobbs HA, Wnuk NM, Hoang JK. Thyroid cancers incidentally detected at imaging in a 10-year period: How many cancers would be missed with use of the recommendations from the Society of Radiologists in Ultrasound? *Radiology* 2014;271:888-94.
27. Ito Y, Miyauchi A, Inoue H, et al. An observational trial for papillary thyroid microcarcinoma in Japanese patients. *World J Surg* 2010;34:28-35.
28. Davies L, Welch HG. Current thyroid cancer trends in the United States. *JAMA Otolaryngol Head Neck Surg* 2014;140:317-22.
29. Miyakoshi A, Dalley RW, Anzai Y. Magnetic resonance imaging of thyroid cancer. *Top Magn Reson Imaging* 2007;18:293-302.
30. Frates MC, Benson CB, Doubilet PM, et al. Prevalence and distribution of carcinoma in patients with solitary and multiple thyroid nodules on sonography. *J Clin Endocrinol Metab* 2006;91:3411-7.
31. Frates MC, Benson CB, Charboneau JW, et al. Management of thyroid nodules detected at US: Society of Radiologists in Ultrasound consensus conference statement. *Radiology* 2005;237:794-800.
32. Cooper DS, Doherty GM, Haugen BR, et al. Revised American Thyroid Association management guidelines for patients with thyroid nodules and differentiated thyroid cancer. *Thyroid* 2009;19:1167-214.
33. Hoang JK, Choudhury KR, Eastwood JD, et al. An exponential growth in incidence of thyroid cancer: trends and impact of CT imaging. *AJNR Am J Neuroradiol* 2014;35:778-83.
34. Ito Y, Miyauchi A, Kihara M, Higashiyama T, Kobayashi K, Miya A. Patient age is significantly related to the progression of papillary microcarcinoma of the thyroid under observation. *Thyroid* 2014;24:27-34.
35. Hoang JK, Raduazo P, Yousem DM, Eastwood JD. What to do with incidental thyroid nodules on imaging? An approach for the radiologist. *Semin Ultrasound CT MR* 2012;33:150-7.
36. Tanpitukpongse PT, Sosa JA, Grady A, Eastwood JD, Choudhury KR, Hoang JK. Incidental thyroid nodules on CT and MRI: discordance between what we report and what receives workup. *AJR Am J Roentgenol*. In press. Accepted on July 31, 2014. Publication date May 2015.
37. Bahl M, Sosa JA, Eastwood JD, Hobbs HA, Nelson RC, Hoang JK. Using the 3-tiered system for categorizing workup of incidental thyroid nodules detected on CT, MRI, or PET/CT: How many cancers would be missed? *Thyroid* 2014. Published ahead of print on September 9, 2014.
38. Kwak JY, Kim EK, Yun M, et al. Thyroid incidentalomas identified by 18F-FDG PET: sonographic correlation. *AJR Am J Roentgenol* 2008;191:598-603.
39. Choi JS, Choi Y, Kim EK, et al. A risk-adapted approach using US features and FNA results in the management of thyroid incidentalomas identified by 18F-FDG PET. *Ultraschall Med* 2014;35:51-8.
40. Kresnik E, Gallowitsch HJ, Mikosch P, Gomez I, Lind P. Technetium-99m-MIBI scintigraphy of thyroid nodules in an endemic goiter area. *J Nucl Med* 1997;38:62-5.
41. Kostoglou-Athanassiou I, Pappas A, Gogou L, Kaldrymides P. Scintigraphy with [111In]octreotide and 201Tl in a Hurthle cell thyroid carcinoma without detectable radio-iodine uptake. Report of a case and review of the literature. *Horm Res* 2003;60:205-8.
42. Sathegke MM, Mageza RB, Muthuphei MN, Modiba MC, Clauss RC. Evaluation of thyroid nodules with technetium-99m MIBI and technetium-99m pertechnetate. *Head Neck* 2001;23:305-10.
43. National Comprehensive Cancer Network. NCC guidelines thyroid carcinoma—nodule evaluation, version 2. 2013. Available at: http://www.nccn.org/professionals/physician_gls/f_guidelines.asp#thyroid. Accessed August 7, 2014.
44. Kwak JY, Han KH, Yoon JH, et al. Thyroid imaging reporting and data system for US features of nodules: a step in establishing better stratification of cancer risk. *Radiology* 2011;260:892-9.
45. Hoang JK, Lee WK, Lee M, Johnson D, Farrell S. US features of thyroid malignancy: pearls and pitfalls. *Radiographics* 2007;27:847-60.